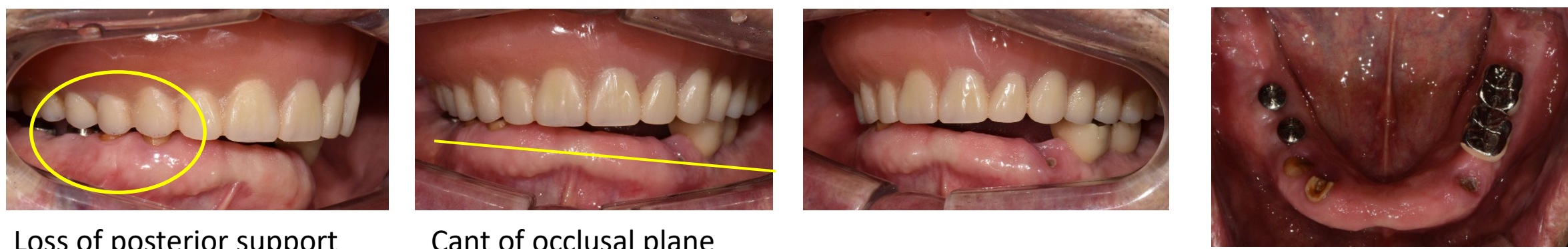


INTRODUCTION

Since multiple tooth loss can cause misalignment of occlusion, loss of vertical height and deflection of mandibular movement, it can be an important treatment goal to restore an appropriate vertical height and occlusion in the centric relation. Implant-assisted removable partial denture is a frequently used clinical technique recently because it increases patient satisfaction by increasing retention, support, and stability of conventional dentures. The objective of this study is to present a case report of a patient who showed satisfactory clinical outcomes describing the fabrication of treatment denture and implant assisted removable partial denture using previously placed implants for a patient with partial loss of posterior support and anterior stop.

METHODS & MATERIAL

<Initial examination>



Loss of posterior support
Incomplete interocclusal distance

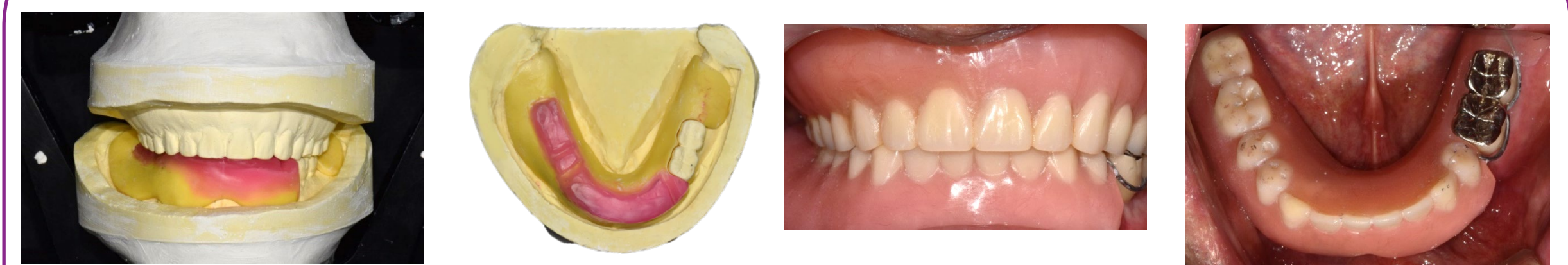Cant of occlusal plane

#44,43,34 residual root

Diagnosis: loss of vertical dimension caused by collapse of posterior support and mandibular unilateral deviation

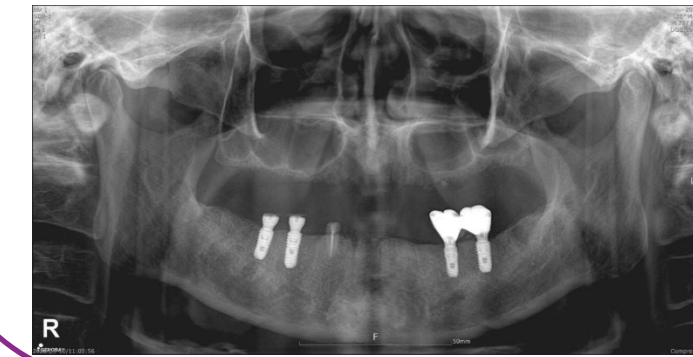
Treatment plan: 1. fabrication of provisional denture and rotated condyle in place
2. Kennedy class I implant- assisted RPD with #35i=36i, #45i=46i surveyed bridge

TREATMENT DENTURE



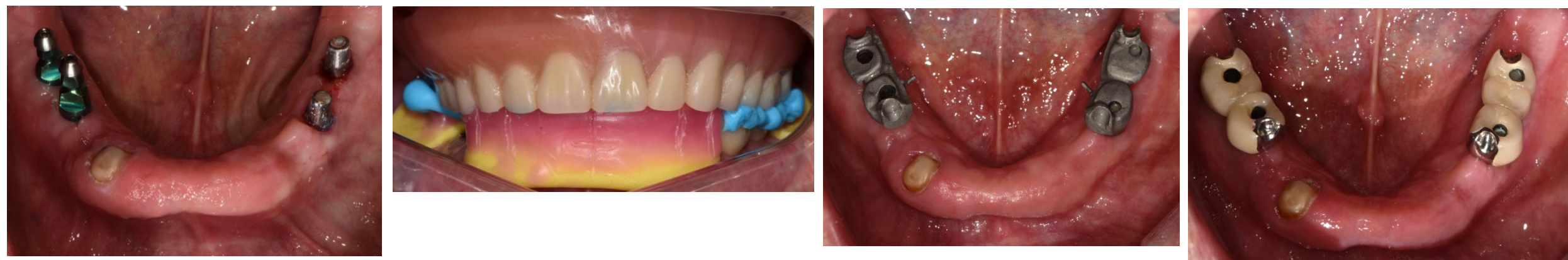
Centric relation record

Treatment denture delivery



#34,44 residual root extraction,
#43 resin capping

IMPLANT SURVEYED BRIDGE



#35i,36i : abutment level impression
#45i,46i : fixture level impression (transfer type)

Centric relation

Metal coping try in

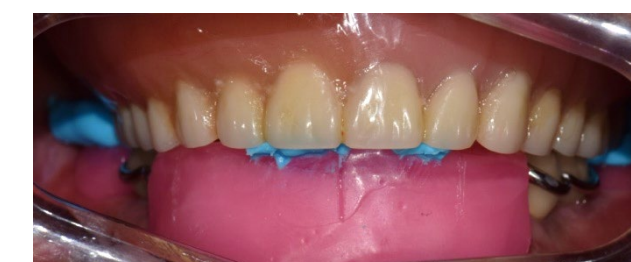Porcelain build up

FINAL DENTURE

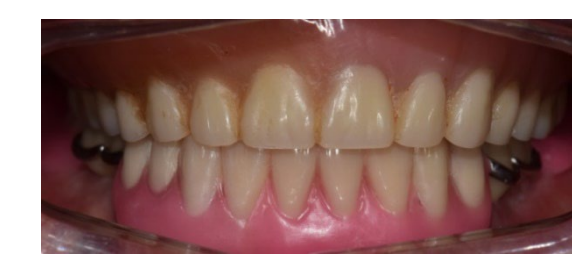

Final impression of IARPD

Framework try-in

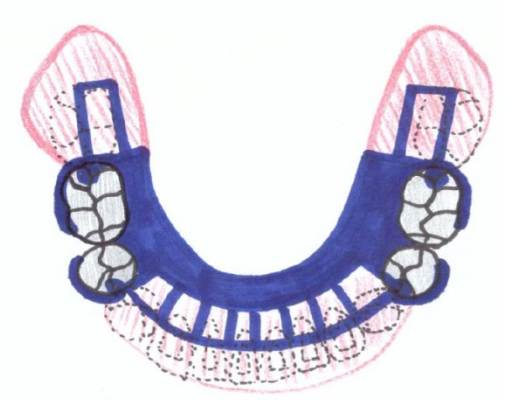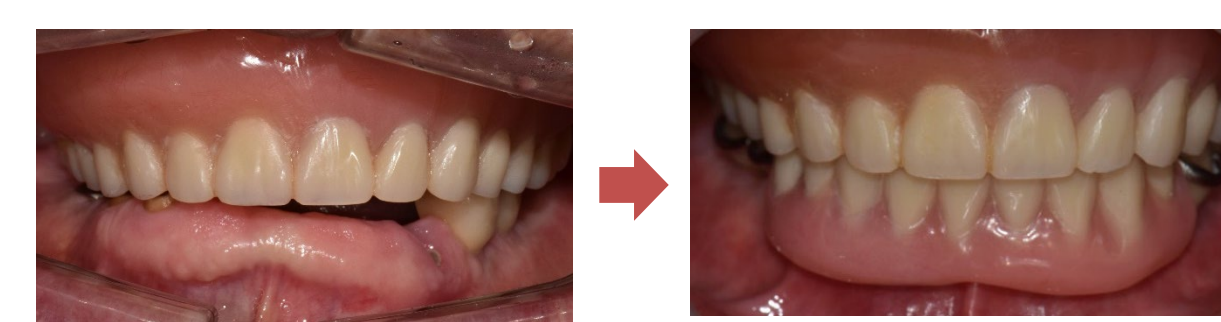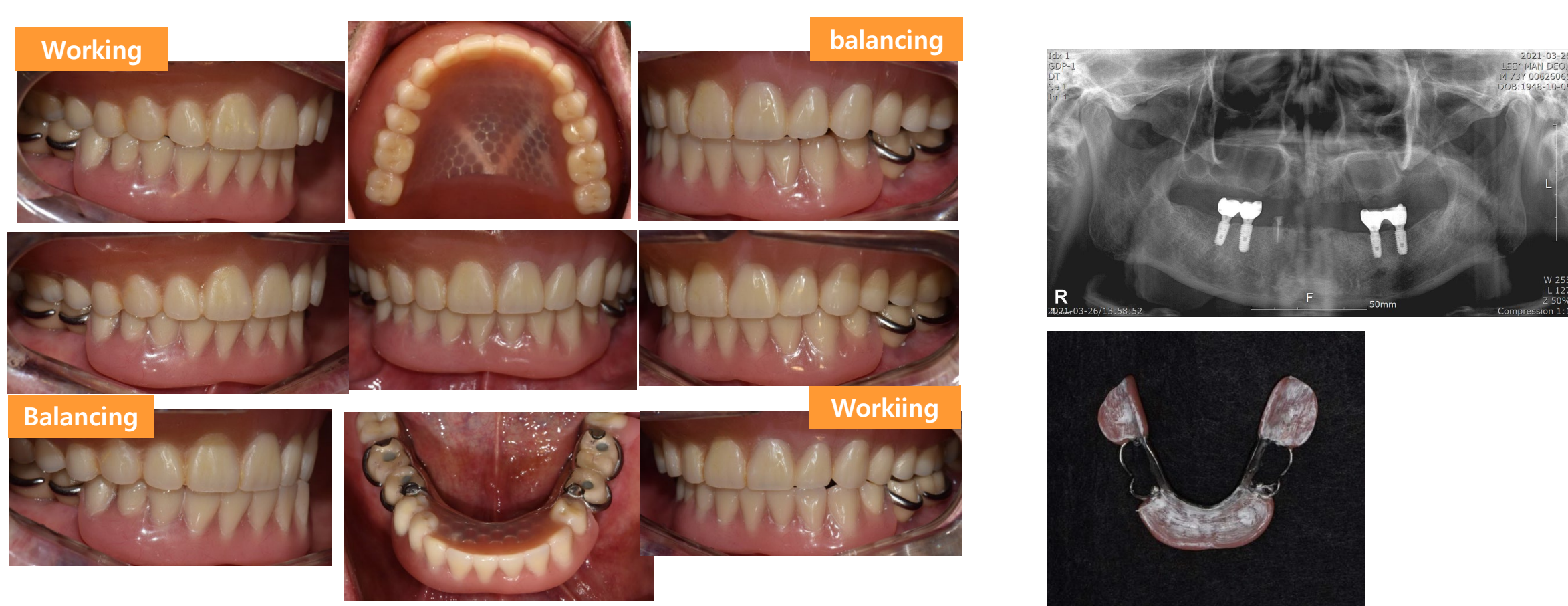


Jaw relation record taking



Wax denture try-in

RESULTS



Design of IARPD

- Correction of mandibular condyle using provisional, treatment denture
- Using implant prostheses as abutment teeth for removable dentures improved masticatory forces and increased patient's satisfaction.

CONCLUSION

In this case, the mandibular condyle was restored to its original position with treatment denture in a patient with loss of vertical dimension and lack of restorative space due to loss of unilateral posterior teeth and anterior teeth in the lower jaw. Implant prostheses were used as abutment teeth for removable dentures. As a result, the stability was greatly improved, the patient's discomfort was reduced, and the rattling movement during mouth opening disappeared, since the condyle stabilized.

Periodic maintenance is needed to manage inflammation around the implant and residual root and to evaluate bone resorption around the implant, and periodic adjustment of dentures is considered essential.

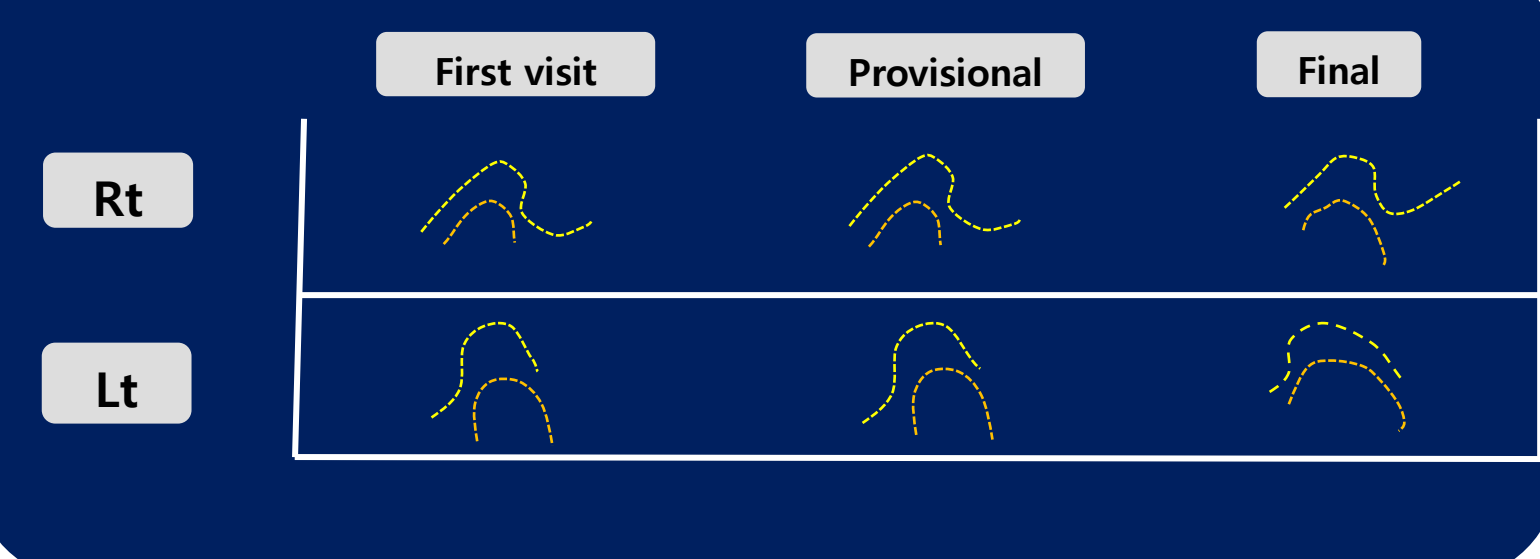


Diagram of mandibular fossa and condyle on rest position traced in transcranial radiograph.

It is found that in provisional denture and final denture, space between articular eminence and mandibular head was more increased than in the first visit.